

Granulomatous Mastitis: A Clinical Case in Pregnancy

Mastite Granulomatosa Idiopática: Um Caso Clínico na Gravidez

Inês Mendes¹, Catarina Gama Pinto¹, Ana Cristina Rodrigues², Lídia Reis¹, Filomena Nunes¹

Hospital de Cascais – Dr. José de Almeida

Abstract

A 38 weeks pregnant woman presents with lump in right breast associated with tenderness, heat and erythema for 1 month. After 2 antibiotic therapy regimens and abscess drainage without improvement, Trucut breast biopsy was performed, whose histological result was Granulomatous Mastitis. Medicated with high-dose, long-lasting corticosteroid therapy, there was improvement of the clinical condition. Idiopathic Granulomatous Mastitis is a rare entity that mimics breast cancer, whose etiology, incidence and treatment are yet to be defined. The knowledge of this disease leads to a timely diagnosis, avoiding unnecessary costs and improving the patient's approach.

Keywords: Granulomatous mastitis; Pregnancy; Corticotherapy; Breast carcinoma.

Resumo

Grávida de 38 semanas apresenta tumefação na mama esquerda associada a dor com 1 mês de evolução. Após 2 esquemas de antibioterapia com drenagem de abscesso sem melhoria procede-se a biopsia mamária Trucut cujo resultado histológico foi de Mastite Granulomatosa. Medicada com corticoterapia em alta dosagem e de longa duração, o quadro clínico teve resolução completa. A Mastite Granulomatosa Idiopática é uma entidade rara, que mimetiza o carcinoma da mama, cuja etiologia, incidência e tratamento ainda estão por definir. O seu conhecimento conduz ao diagnóstico atempado evitando custos desnecessários e melhorando a abordagem da doente.

Palavras-chave: Mastite granulomatosa; Gravidez; Corticoterapia; Carcinoma da mama.

INTRODUCTION

Idiopathic granulomatous mastitis is a rare entity that clinically and radiologically mimics breast cancer. Rarely associated with pregnancy, this clinical case shows the importance of thinking about this condition in order to avoid unnecessary conduct associated with the most frequent cancer in women.

CASE REPORT

A 23-year-old female, without relevant personal and family history, G3, P1,A1 (normal delivery 2 years ago, breastfeed for 6 months).

She goes to the emergency room, 38 weeks pregnant, for diffuse pain in the right breast with 1 month of evolution associated with an increasing lump. On examination, the superior-external quadrant of the right breast showed a painful swelling associated with edema, heat and redness, for which she was medicated empirically with amoxicillin + clavulanic acid for seven days, without clinical improvement. On the next

1. Serviço de Ginecologia e Obstetria, Hospital de Cascais – Dr. José de Almeida.

2. Serviço de Anatomia Patológica, Hospital de Cascais – Dr. José de Almeida.

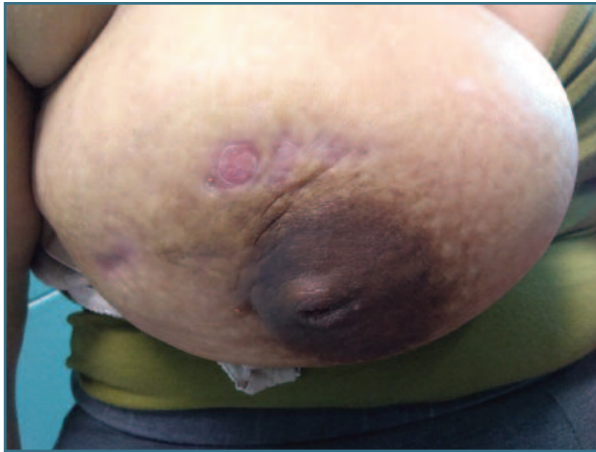

FIGURE 1. Right breast with persistent thickening of the upper outer quadrant associated with inflammatory skin lesions

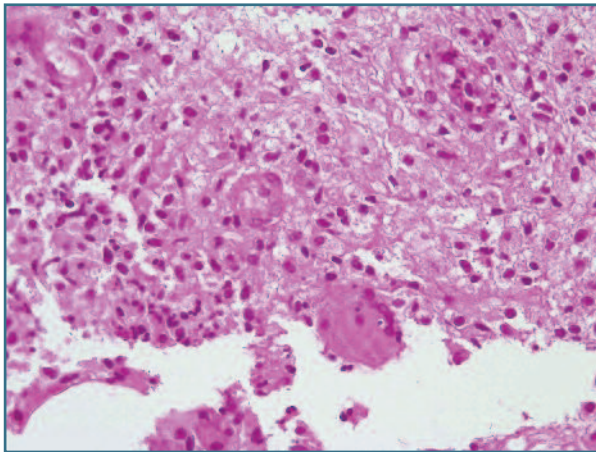


FIGURE 2. Breast fragments consisting of adipose tissue. There is an inflammatory process with epithelioid granulomas. The inflammatory infiltrate consists of lymphocytes, plasma cells, some polymorphonuclear cells and histiocytes. PASD and Ziehl Neelsen stains and AE1/AE3 immunohistochemistry were negative.

day, after medical appointment, she started a new scheme with clindamycin.

One week after starting treatment with clindamycin, the breast lesion worsens, this time showing a fluctuation zone. We decided to perform a surgical drainage, after two weeks of starting antibiotic therapy, in the operating room of the emergency unit. When draining the abscess, purulent content with a foul odor emerges in abundance.

The pregnant woman remained always afebrile, with negative inflammatory parameters (leucocytes and

C-reactive protein). The culture of the exudate drained was negative for aerobic, anaerobic microorganisms, as well as fungal culture.

At the breast specialist appointment, she presented a persistent thickening of the right breast's upper outer quadrant associated with inflammatory skin lesions (Figure 1). Pouch and Trucut biopsies were performed. Meanwhile, corticosteroid therapy was started with prednisolone 40 mg per day due to a presumptive diagnosis of an Idiopathic Granulomatous Mastitis.

The breast echography showed a subcutaneous collection with a small depth trajectory.

The histological results confirmed the diagnosis of Idiopathic Granulomatous Mastitis (Figure 2), and the following therapeutic regimen of corticosteroid therapy was proposed to the patient: 60 mg/day 2 months, 50 mg/day 1 month, 40 mg/day 1 month, 30 mg/day 1 month, 20 mg/day 1 month, 10 mg/day 2 months; due to persistence of the slurry of the breast, azathioprine 50 mg 12/12h was associated after two weeks.

After improvement of the skin lesions and the swelling of the right breast, one month of the beginning of corticoid therapy, the patient decided to stop the corticoid and immunosuppressive sparing therapy, with the swelling worsening within 1 week.

The corticosteroid therapy was restarted with complete resolution of symptoms after 6 months. Currently, about 2 years later, she had another pregnancy and remains asymptomatic.

DISCUSSION

Idiopathic Granulomatous Mastitis is a rare entity that mimics breast cancer, whose etiology, incidence and treatment are yet to be defined.

First described by Kessler and Wolloch in 1972, one of the possible etiologies of this disease is an inflammatory response to milk proteins and lipids, having a strong correlation with pregnancy and lactation. In opposite of this case, this condition rarely happens in pregnancy, being more usual 6 months to 2 years after breastfeeding¹.

Other causes have been proposed for this entity: autoimmune disease, oral contraceptives, trauma, infection, diabetes, smoking, hyperprolactinemia, and alpha-1 antitrypsin deficiency¹.

Although its incidence is unknown, it affects mostly women of childbearing age, which contrasts with breast cancer, whose peak age is later².

As in the present case, it manifests as a swelling, which may be accompanied by pain and other inflammatory signs, skin changes and adenopathies, making the differential diagnosis with breast cancer mandatory, namely inflammatory breast carcinoma³.

The echographic findings were benign in this clinical case, however it is usual to manifest as a mass with irregular shape and contour, also making the differential diagnosis with breast cancer difficult.²

The gold standard method for diagnosis is the histology diagnosis⁴.

Diagnosis is made by the histological pattern of breast lobes surrounded by granulomatous inflammation without caseous necrosis, excluding: Brucellosis, Bartonella, tuberculosis, sarcoidosis, Wegener's granulomatosis, fungal infections^{1,5,6}.

The treatment, also non-consensual, can be medical and/or surgical. Surgical treatment consists of abscess drainage and even excision of the affected area. Medical treatment involves the use of antibiotics and immunosuppressive therapy, corticosteroids and antimeabolites such as azathioprine and methotrexate. Corticosteroids in high doses (60 mg with progressive decrease) for periods of 3 to 6 months are recommended⁶ – the present case reflects the need to maintain immunosuppressive therapy in order to avoid relapses.

The simultaneous existence of breast carcinoma and granulomatous mastitis is rare, with only about 5 published cases in the literature where these two entities coexist⁴.

Finally, knowledge of this disease is essential: its timely diagnosis avoids unnecessary costs and improves the patient's approach.

Patient has given informed consent for publication of this clinical information and related pictures.

REFERENCES

1. Pluguez-Turull, C. W. et al. Idiopathic granulomatous mastitis: Manifestations at multimodality imaging and pitfalls. *Radiographics* 38, 330-356 (2018).
2. Alikhassii, A., Azizi, F. & Ensani, F. Imaging features of granulomatous mastitis in 36 patients with new sonographic signs. *Journal of Ultrasound* 23, 61-68 (2020).
3. Ozsen, M., Tolunay, S. & Gokgoz, M. S. Case Report: Ductal Carcinoma in Situ Within A Granulomatous Mastitis. *European Journal of Breast Health* (2018) doi:10.5152/ejbh.2018.3894.
4. Oddó, D., Domínguez, F., Gómez, N., Méndez, G. P. & Navarro, M. E. Granulomatous lobular mastitis associated with ductal carcinoma in situ of the breast. *SAGE Open Medical Case Reports* 7, 2050313X1983658 (2019).
5. Breucq, C., Verfaillie, G., Bourgain, C., Ernst, C. & Stadnik, T. Mastitis Granulomatosa. *The Breast Journal* vol. 11 (2005).
6. Aydin, I. et al. Idiopathic Granulomatous Lobular Mastitis: An Imitation of Breast Carcinoma. *Cureus* (2021) doi:10.7759/cureus.15206.

AUTHORS' CONTRIBUTIONS

Inês Mendes: Performed literature search and Writing of the manuscript. Catarina Gama Pinto: Conceived the idea and contributed to revisions. Ana Cristina Rodrigues: Pathology diagnosis and contributed to revisions. Lídia Reis: Conceived the idea and contributed to revisions. Filomena Nunes: Contributed to revisions

AUTHORS DISCLOSURE

No potential conflict of interest relevant to this article was reported.

CORRESPONDENCE TO:

Inês Mendes
E-mail: inesazevedo_9@hotmail.com
<https://orcid.org/0000-0002-8248-6803>

RECEIVED: 08/04/2022

ACCEPTED: 08/06/2022